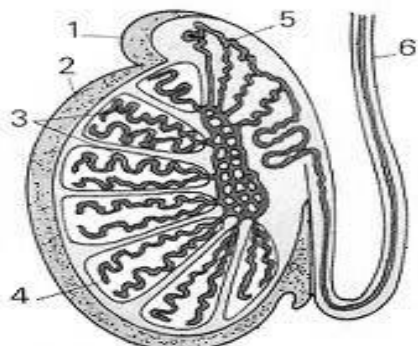
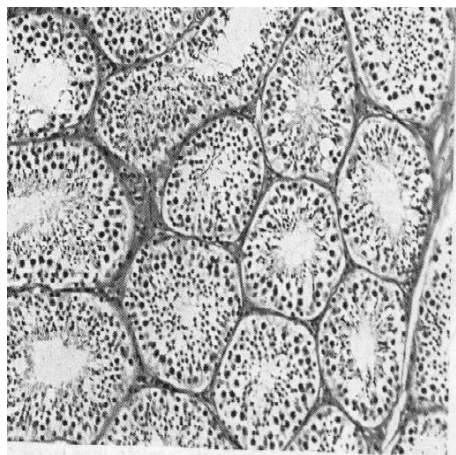
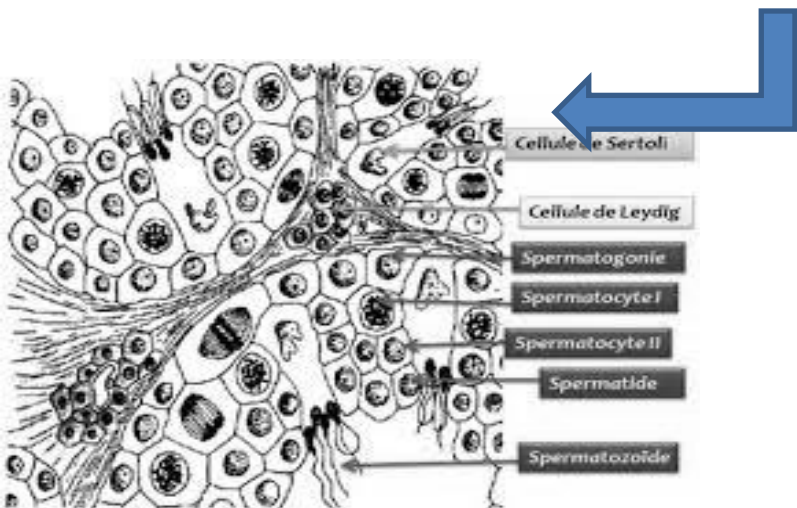
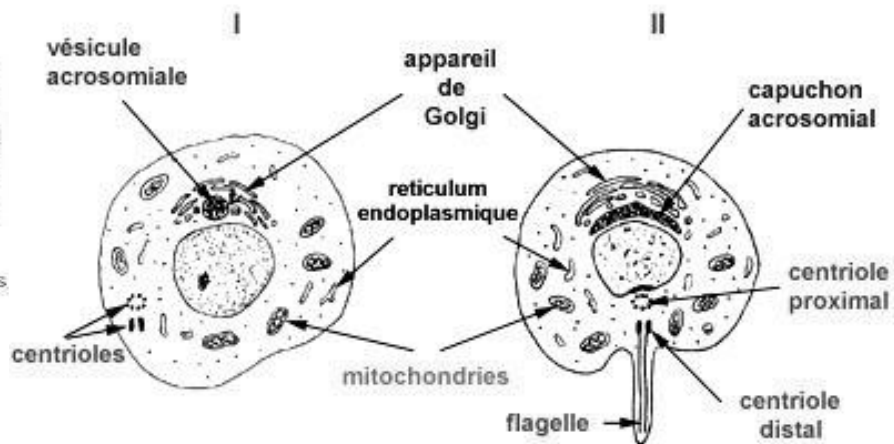


Spermatogenèse

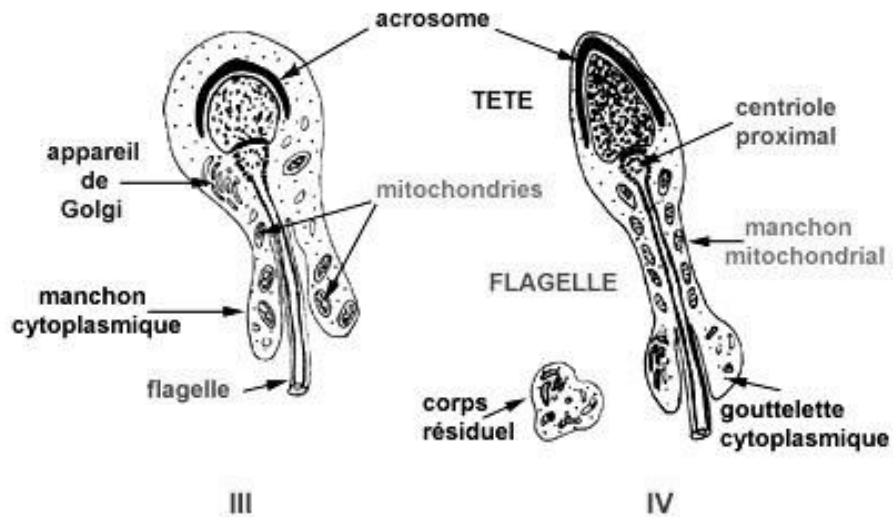


1 - épидidyme. 2 - testicule. 3 - tubes séminifères. 4 - lobule testiculaire. 5 - canal de l'épididyme. 6 - canal déférent.

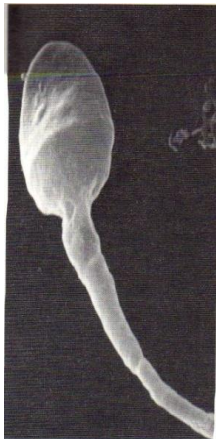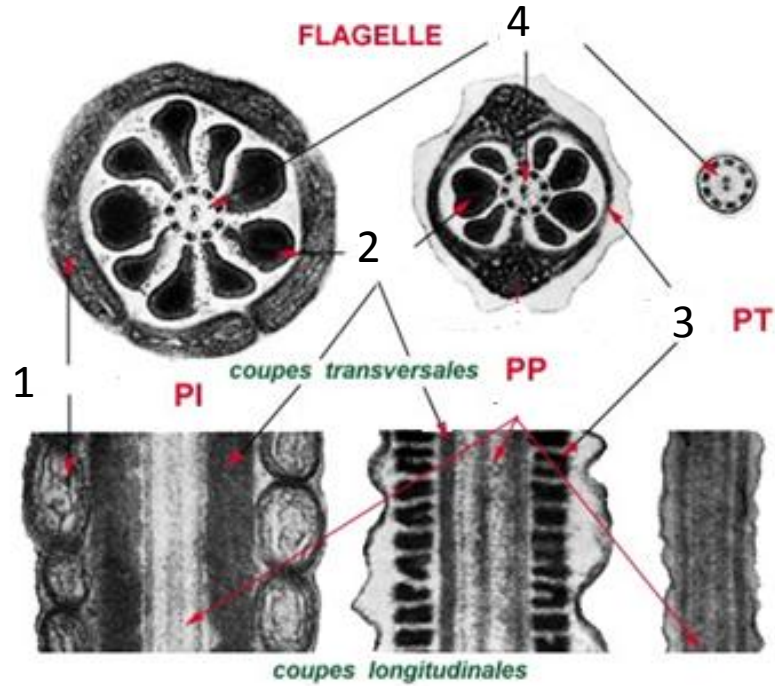
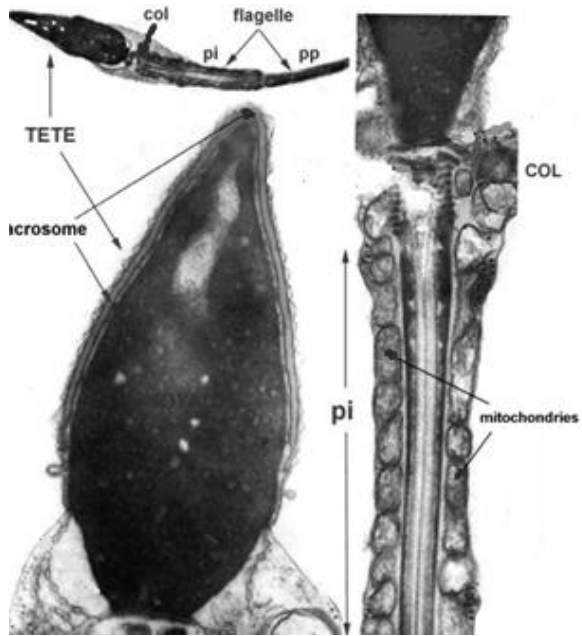
3-



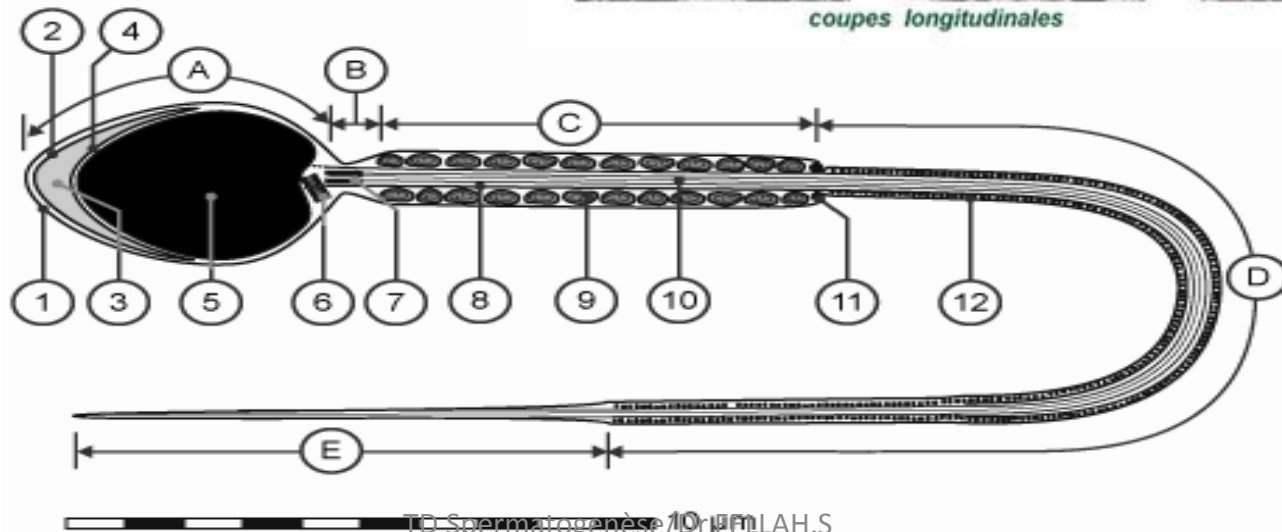
Cellule de Sertoli
Cellule de Leydig
Spermatogonie
Spermatocyte I
Spermatocyte II
Spermatide
Spermatozoïde



4-

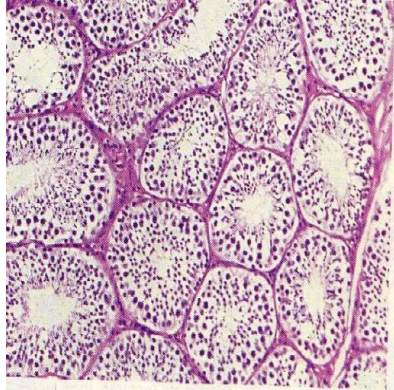
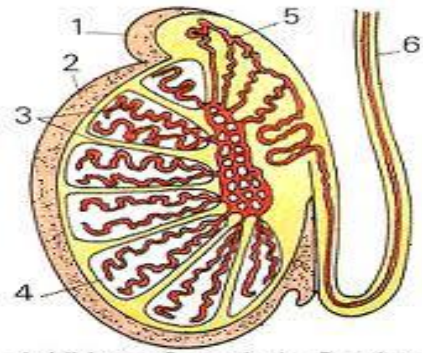


Observation au MEB



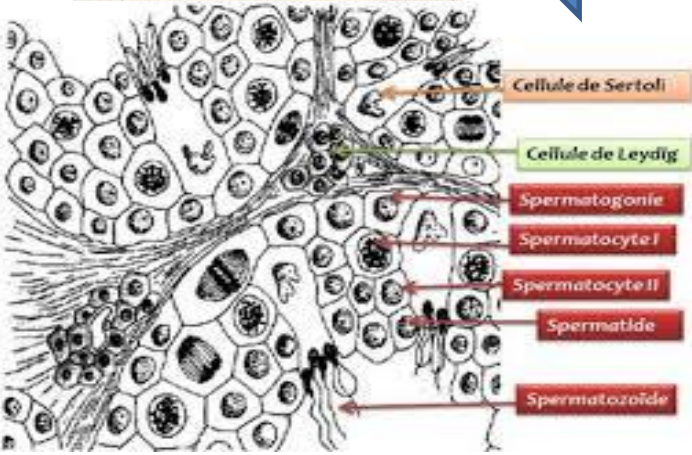

TD Spermatogénèse / Dr. P. LAH.S

Spermatogénèse

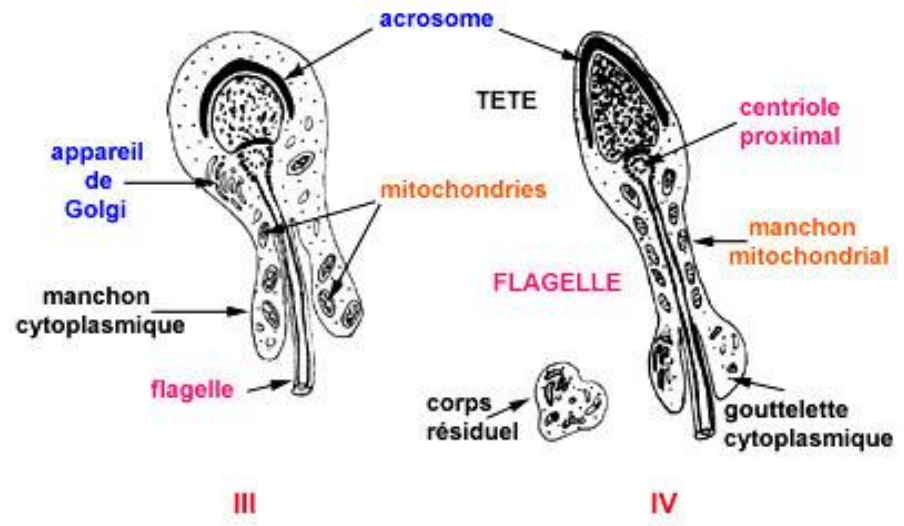
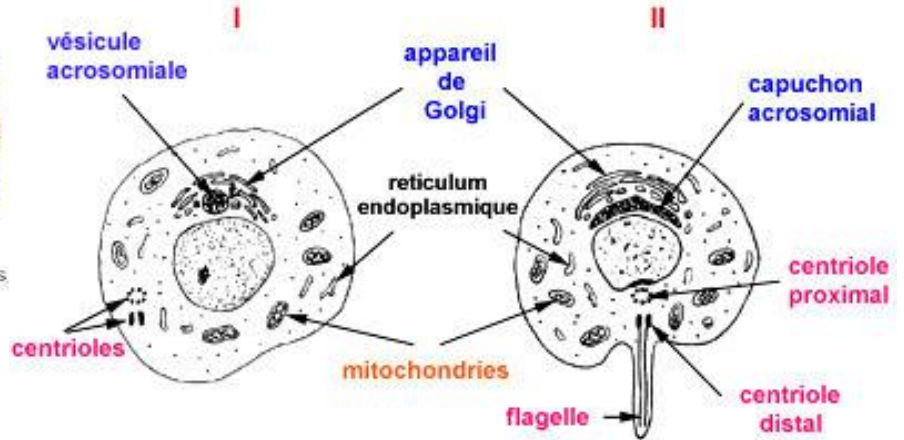


1 - épидидyme. 2 - testicule. 3 - tubes séminifères. 4 - lobule testiculaire. 5 - canal de l'épididyme. 6 - canal déférent.

1-



2-

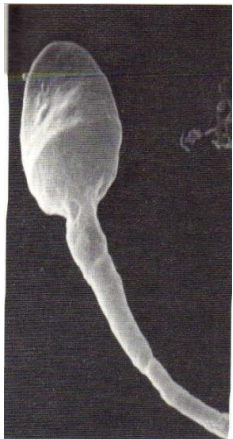
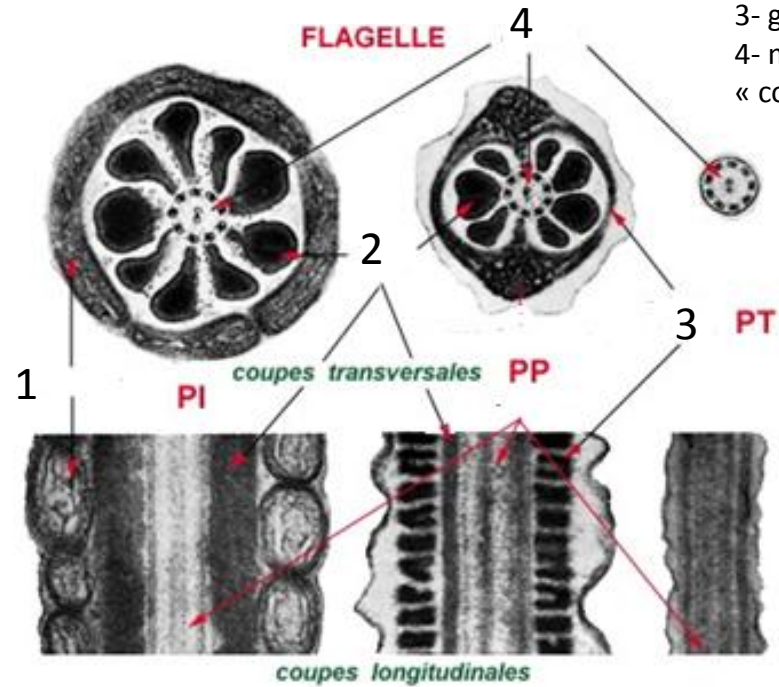
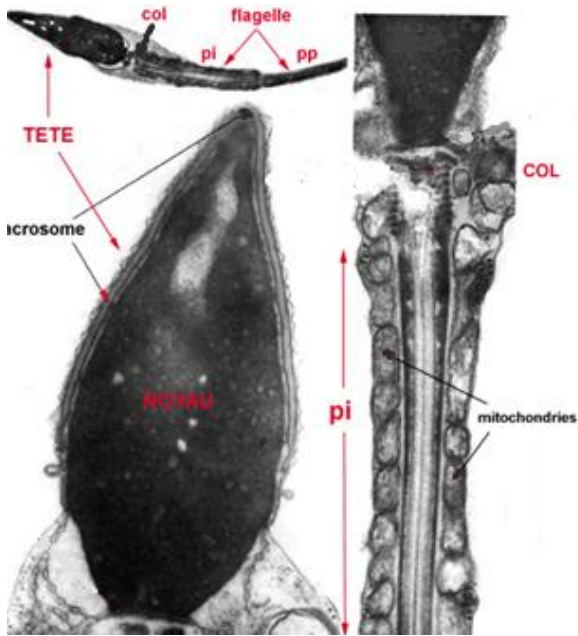


3-

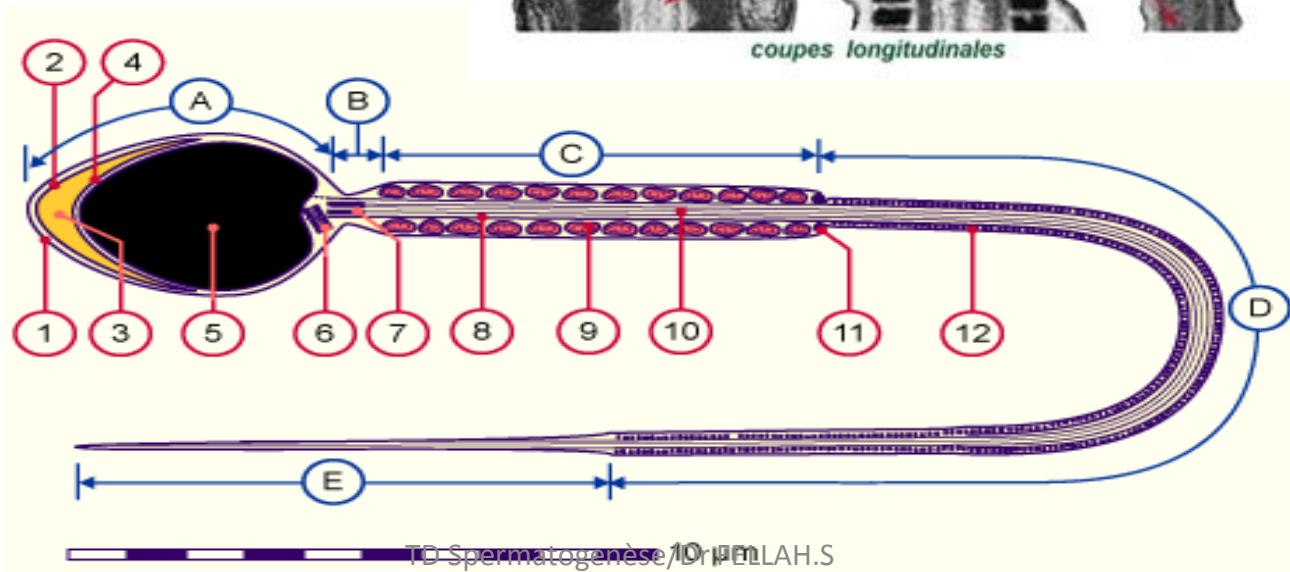
Spermatogénèse

Ultrastructure du spermatozoïde

- 1-mitochondries
- 2- fibres denses
- 3- gaine fibreuse
- 4- microtubules « complexe axial »



Observation au MEB



TD Spermatogénèse, Dr. P. LAH.S